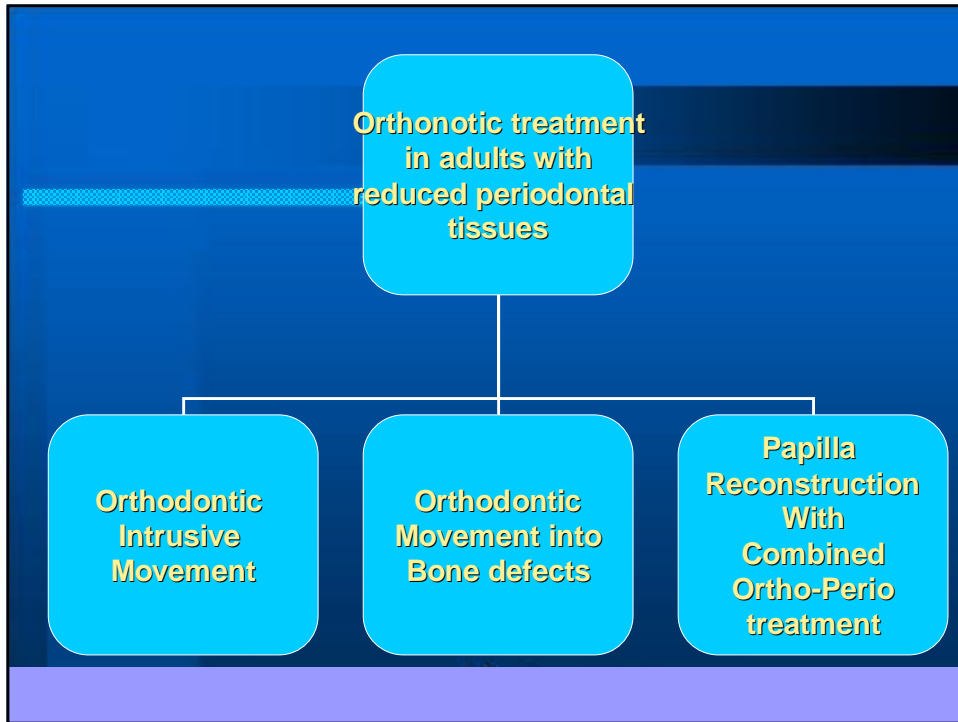


الله جميل و يحب الجمال



Orthodontic treatments in periodontally compromised patients

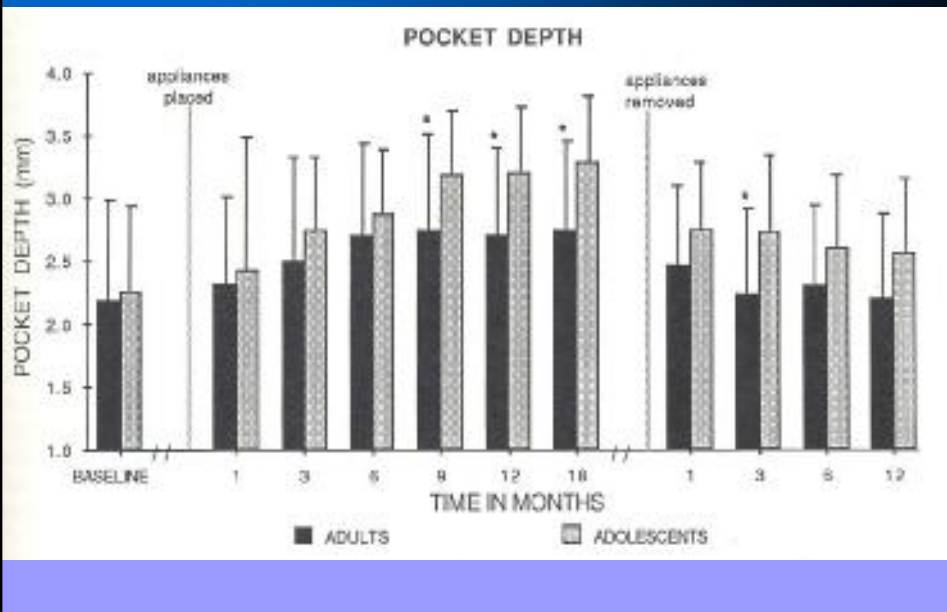
- | By: Reza Amid
- | Department of Periodontics
- | Shiraz Dental Faculty
- | Nov 2006



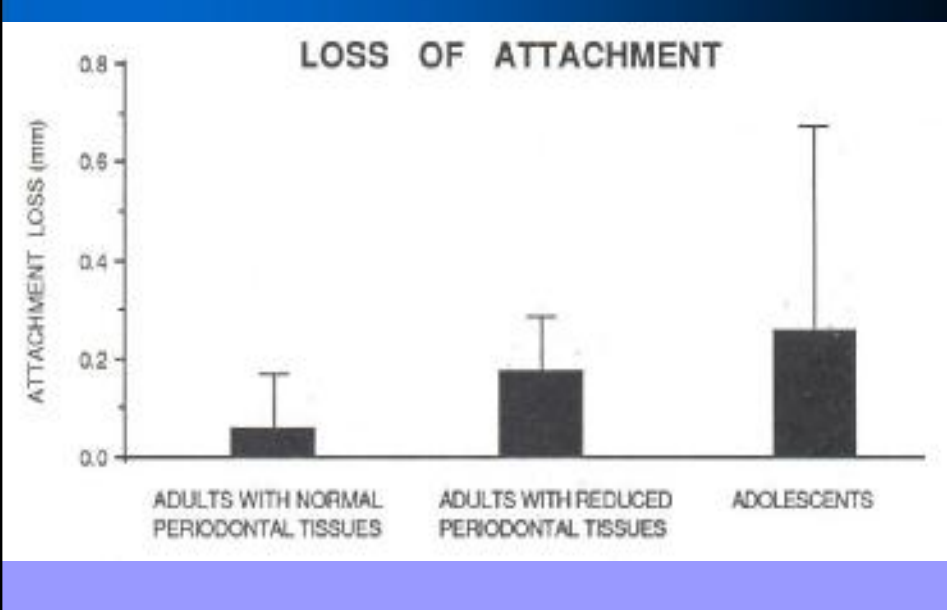
Introduction

- | More than 20% of orthodontic patients are adults
- | More than 75% of adults older than 40 years of age have periodontal disease

Boyd RL & et al
University of California



Boyd RL & et al
University of California



Conclusion

- | Mean PD increased slightly during ortho treatment for adults (0.5 mm)
- | Probably a response to the increased supragingival plaque and gingival inflammation during the first 6 months of treatment.
- | PD returned to baseline levels after appliances were removed.

Conclusion

- | Prerequisites:
- | Periodontal treatment to arrest active disease before orthodontic treatment.
- | Monthly reinforcement of plaque removal.
- | Subgingival debridement at 3-month intervals, considering repopulation of subgingival pathogenic bacteria.

Periodontal response to Orthodontic Force

Lindhe comments

- | Strong force beyond capillary blood pressure

 - | PDL crushed

 - | Hyalinization

 - | Delayed tooth Move

- | Light force (20-25 mmHg)

 - | PDL ischemia

 - | Simultaneous bone formation and resorption

Periodontal response to Orthodontic Force

Lindhe comments

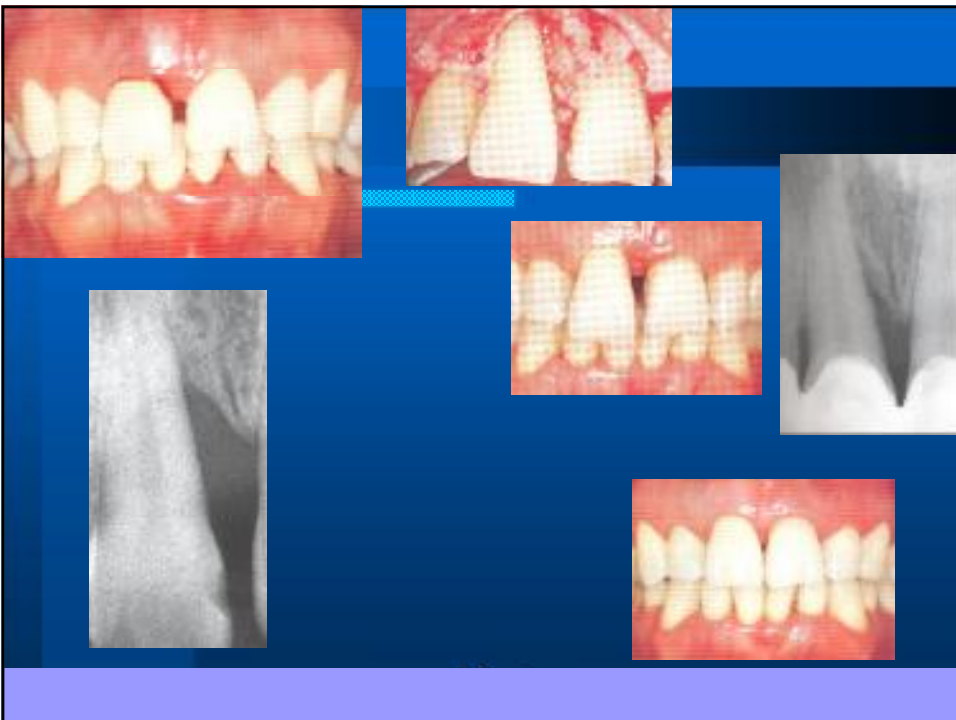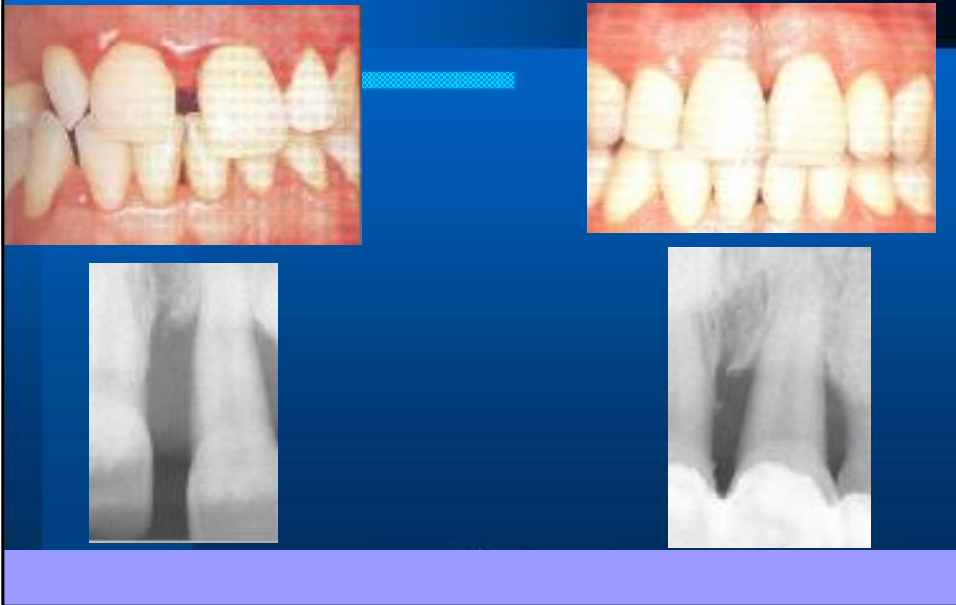- | Initial stage: interrupted force of 20-30 g

- | 30-50 g in tipping and

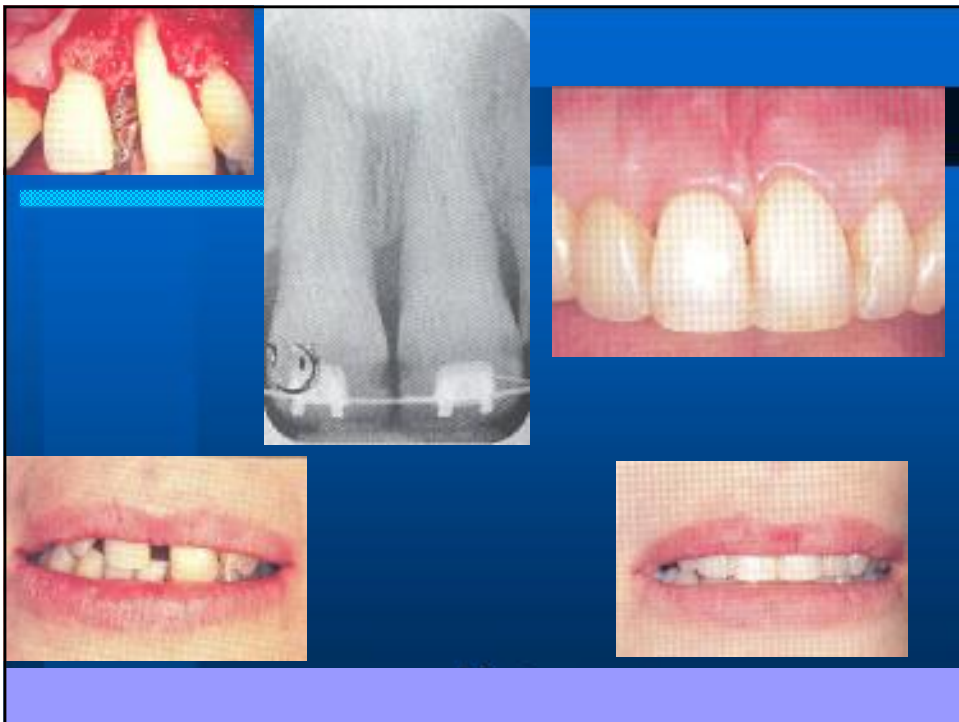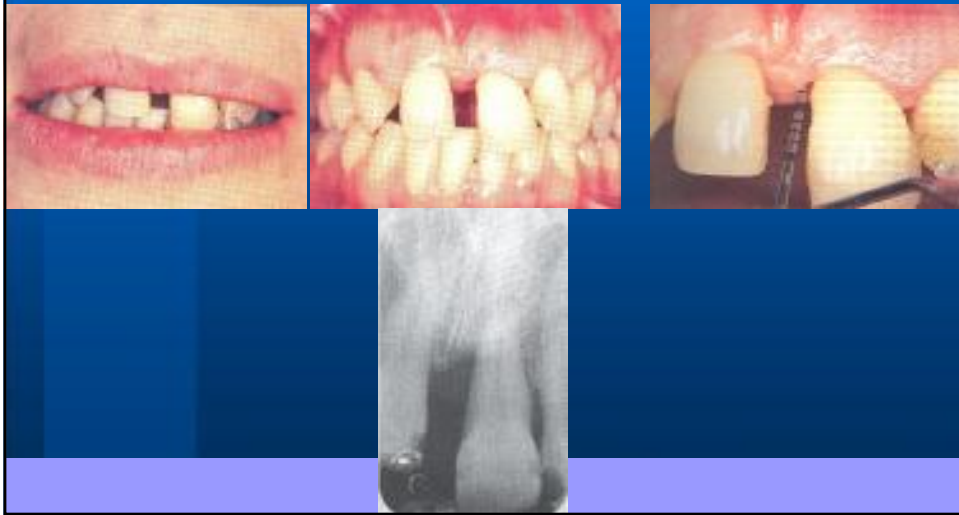- | 50-80 g in bodily movements

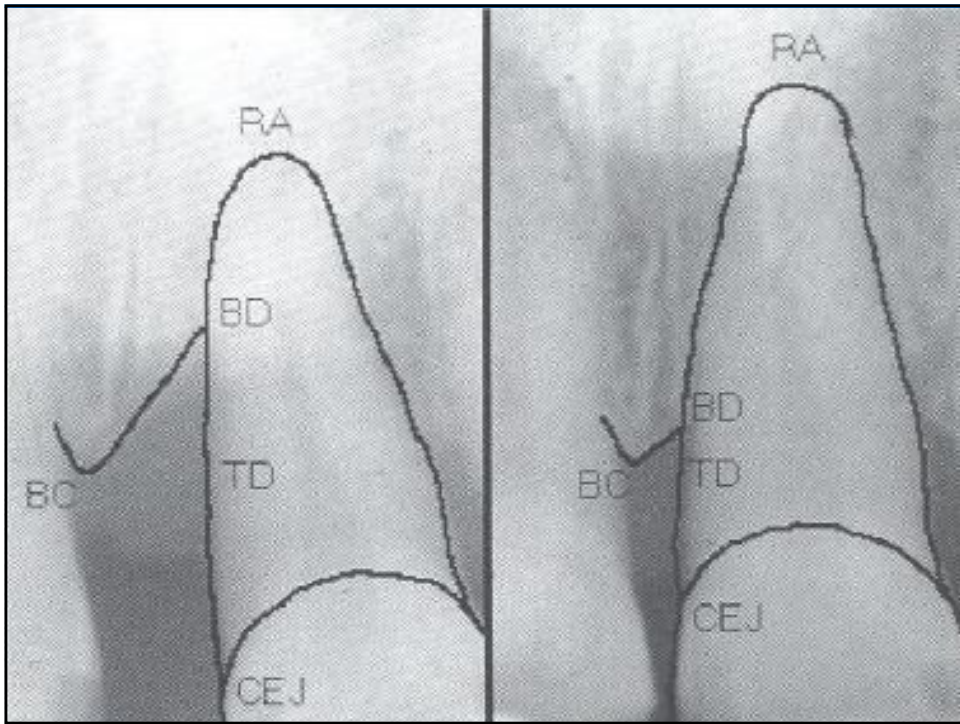
- | A distance of movement of 0.5-1.0 mm per month

Stefania R. & et al 2000

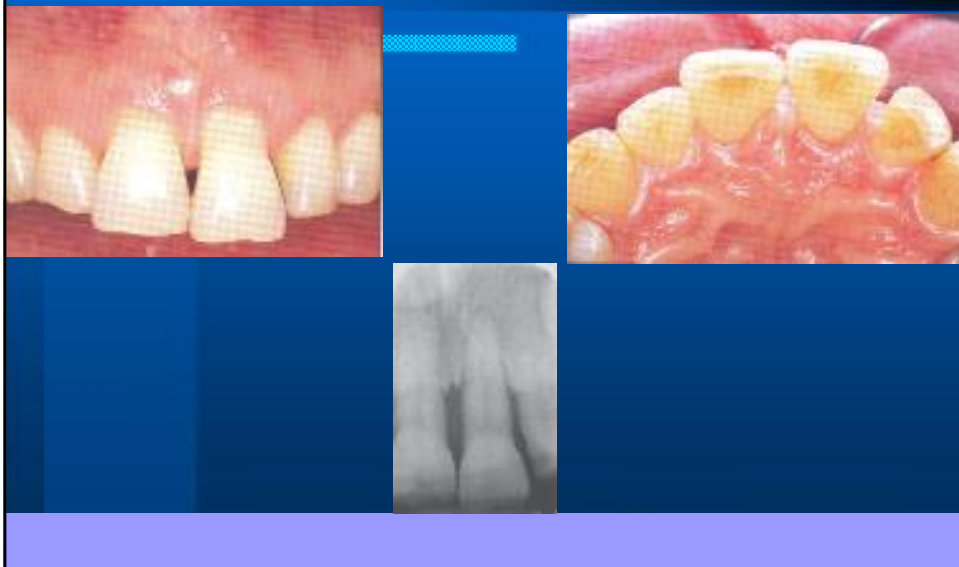


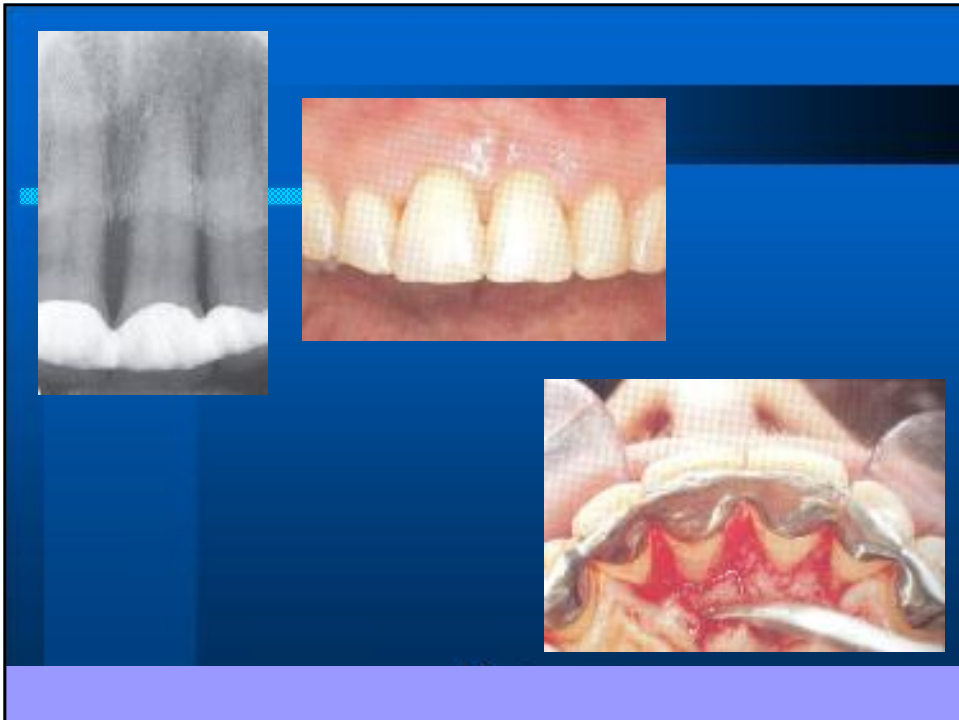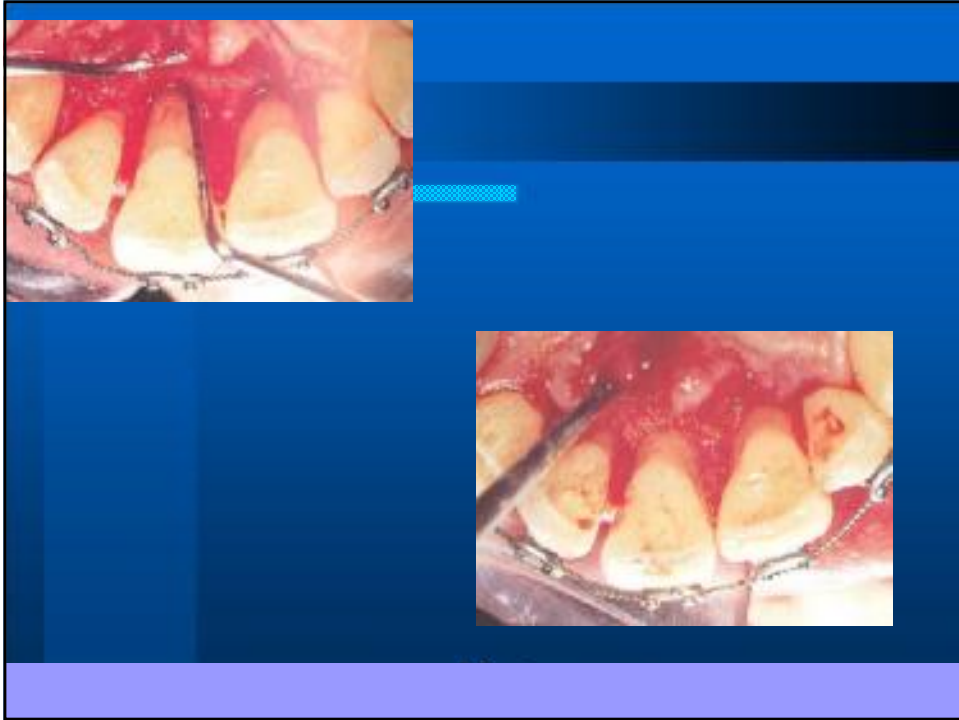Orthodontic Intrusive Movement to reduced infrabony pockets



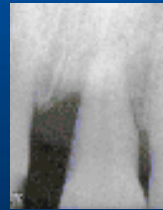
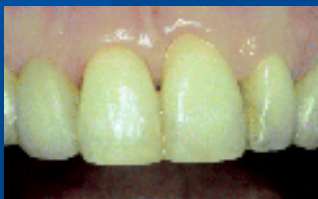
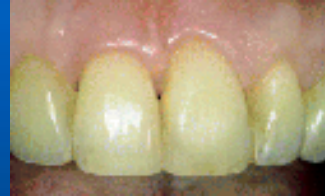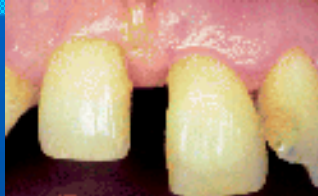Orthodontic Intrusive Movement After GTR to reduced infrabony pockets

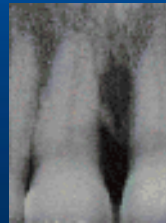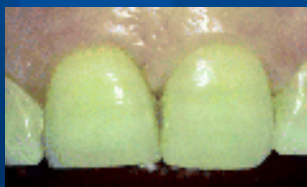

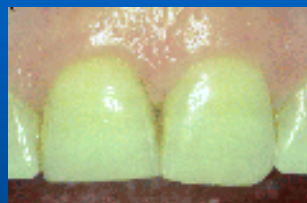
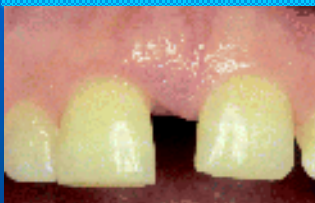

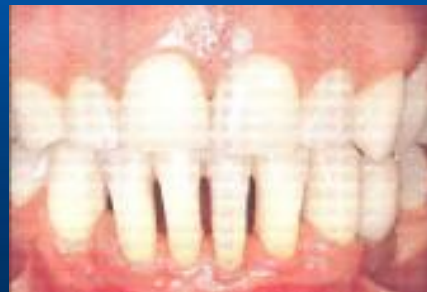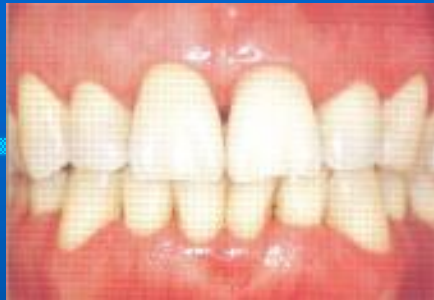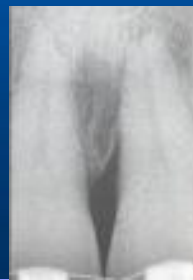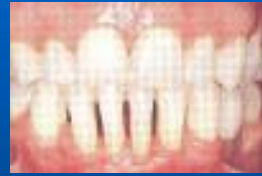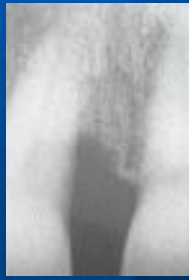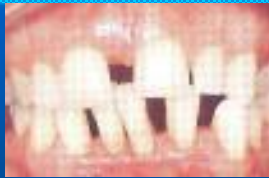Reconstruction of Maxillary Midline Papilla



Reconstruction of Maxillary Midline Papilla



Reconstruction of Maxillary Midline Papilla



Aggressive Periodontitis

